

8° NeuroMeeting

Riparare il cervello: nuove frontiere terapeutiche

Napoli 12 e 13 Maggio 2016

La terapia genica

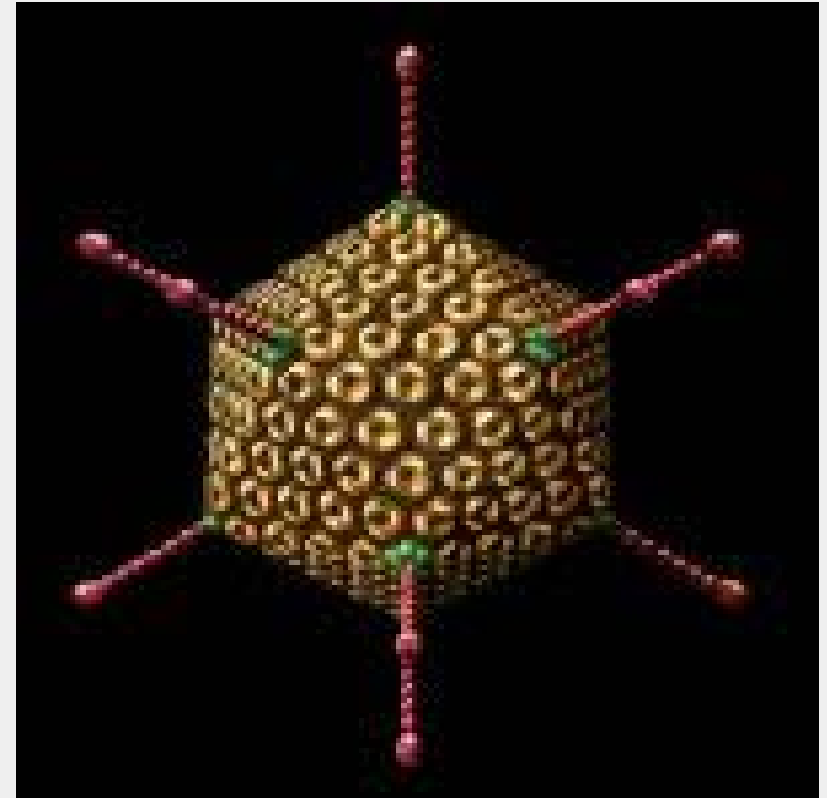
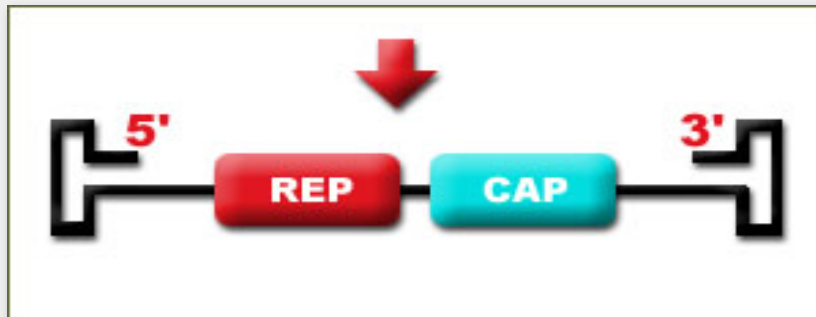
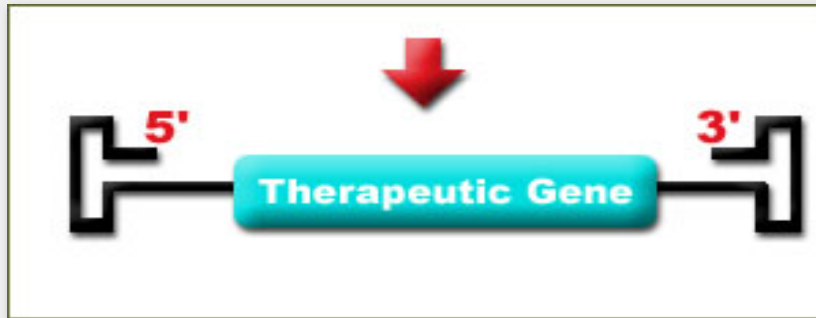Francesca Simonelli

**Direttore clinica oculistica
Seconda Università degli Studi di Napoli**

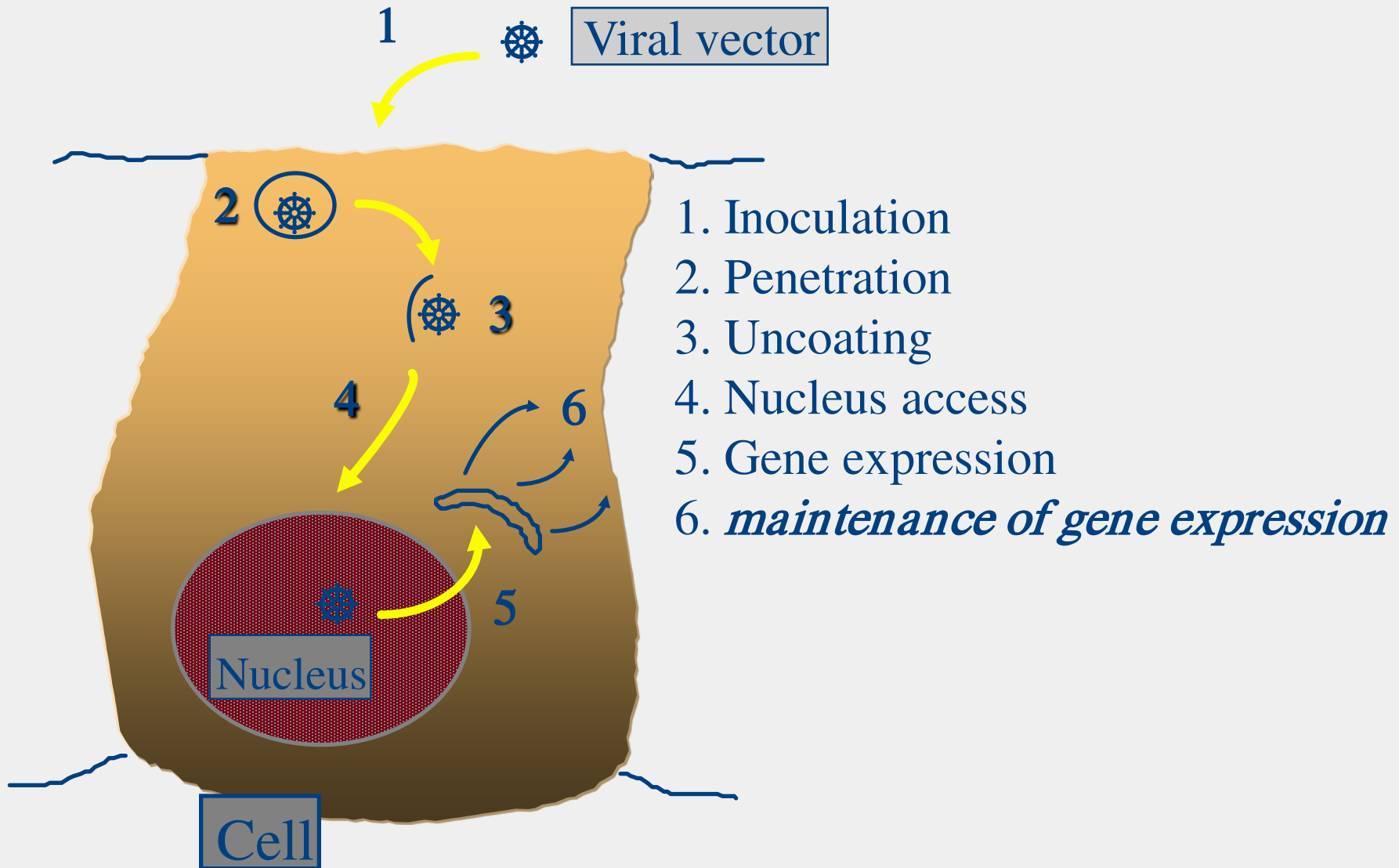
Gene Therapy

Gene therapy consists of inserting exogenous Nucleic acid to specific cell tissues in order to synthesize a biologically active protein

Viral vector

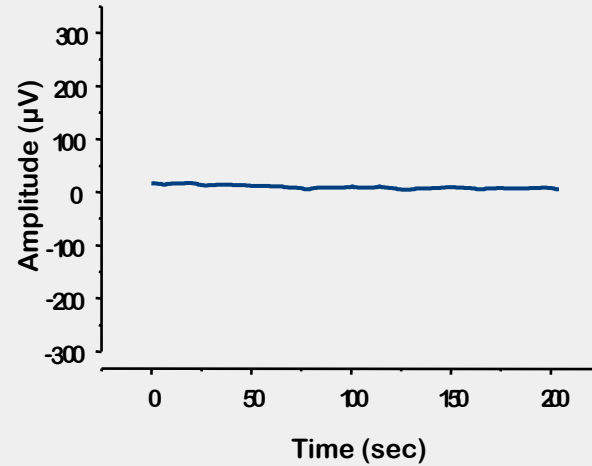


Gene transfer

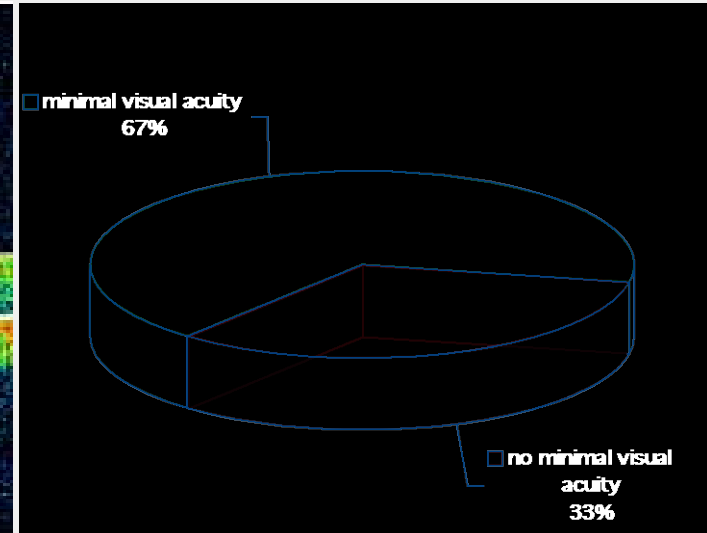
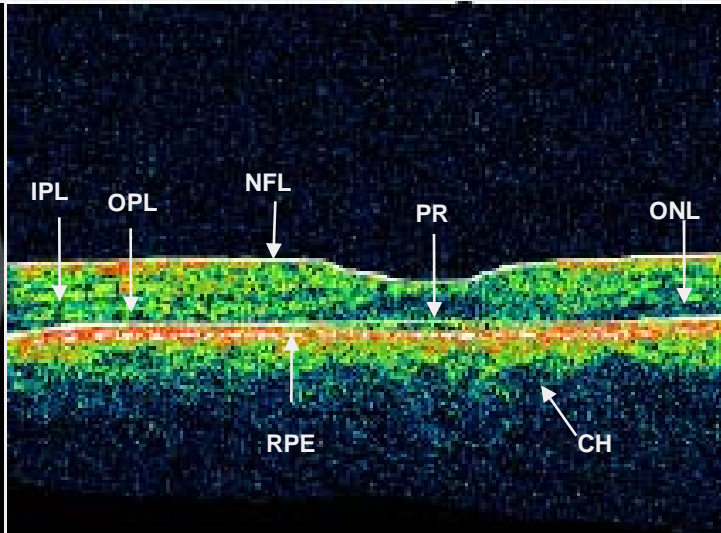
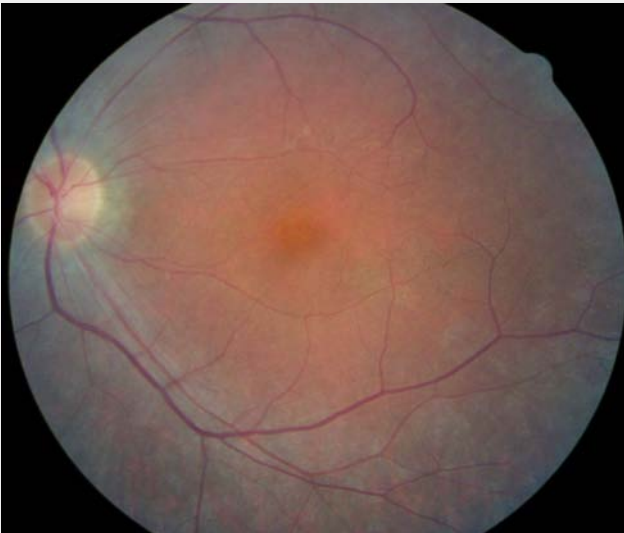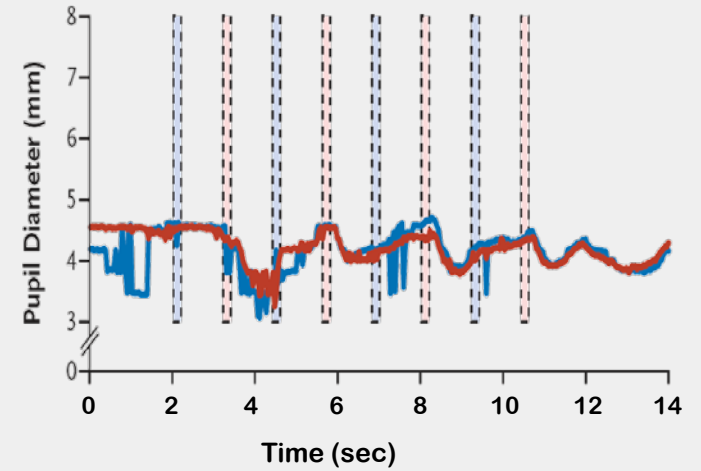


Clinical Features of Leber Congenital Amaurosis patients

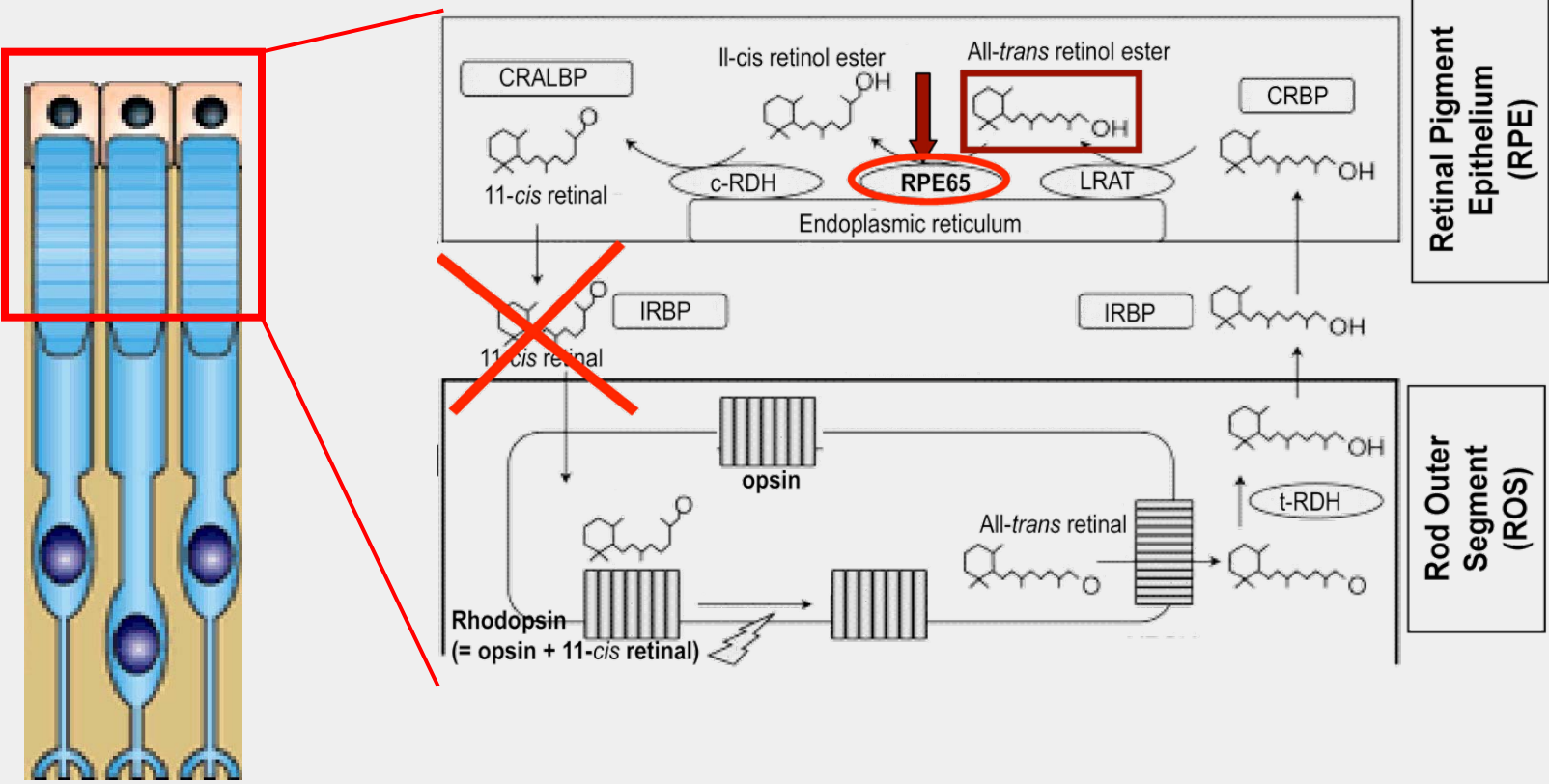
Electroretinogram



Pupillometry



RPE65 is necessary for production of 11-cis-retinol, a component of rhodopsin



Phase I open-label dose escalation safety study of gene transfer in subjects with LCA due to RPE65 mutation

- GMP Vector manufactured at Center for Cellular and Molecular Therapeutics of Philadelphia
- Patients identified at CHOP, TIGEM, Second University of Naples
- Subretinal administration performed at Children's Hospital of Philadelphia
- Follow-up tests performed at CHOP and at Second University of Naples

INCLUSION CRITERIA

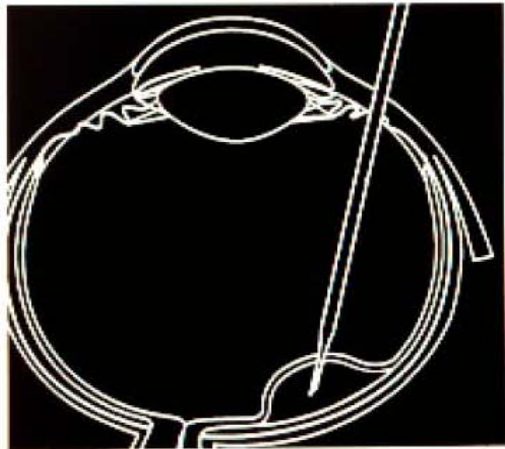
1. Adhere to protocol and companion protocol for long-term follow-up as evidenced by written informed consent or parental permission and subject assent.
2. Adults and children diagnosed with LCA.
3. Molecular diagnosis of LCA due to RPE65 mutations by a CLIA-approved laboratory.
4. Age eight years old or older at the time of administration.
5. Visual acuity $\leq 20/160$ or visual field less than 20° in the eye to be injected.

Summary of patient demographics

	Low dose			Medium dose					High dose			
	NP01	NP02	NP03	NP04	CH06*	CH08	CH09	CH10	CH11	CH12	CH13	NP15
Date at administration	Oct 11, 2007	Dec 13, 2007	Jan 24, 2008	April 10, 2008	May 22, 2008	July 10, 2008	Sept 25, 2008	Nov 18, 2008	Dec 30, 2008	March 5, 2009	April 16, 2009	June 2, 2009
Age (years)	26	26	19	17	20	9	8	10	24	44	35	11
Sex	Female	Male	Female	Male	Female	Male	Male	Male	Female	Female	Male	Male
RPE65 mutations	E102K/ E102K	E102K/ E102K	R234X/ R234X	R91W/ T149N	IVS1+5g>a/ L341S	F530fs/F530fs	R124X/ Lys297del1aggA	IVS1+5g>a/ Phe530del1ttc	V473D/ V473D	K303X/ W431C	IVS1+5g>a/ IVS1+5g>a	D167W/ H313R
Injected eye†	Right	Right	Right	Left	Right	Right	Left	Right	Right	Right	Right	Right

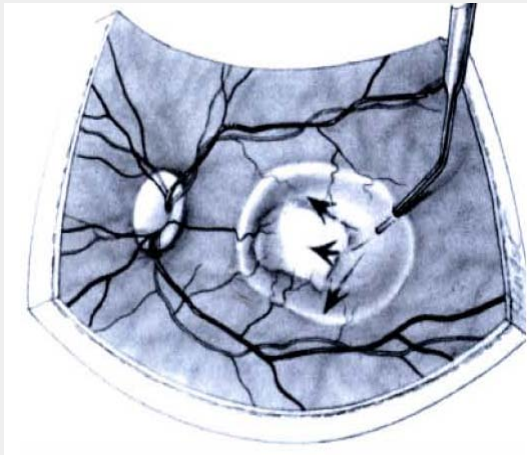
†Eye with worst sight selected for surgery.

Subretinal Injection of AAV2.hRPE65v2



We did a standard three-port pars plana vitrectomy, with removal of the posterior cortical vitreous.

Patients in the low-dose cohort were injected with 1.5×10^{10} vector genomes and those in the medium-dose with 4.8×10^{10} vector genomes of AAV2-hRPE65v2 in a volume of 150 μL into the subretinal space.



Patients in the high-dose cohort were injected with 1.5×10^{11} vector genomes in a volume of 300 μL .

RESULTS

Safety profile

- None of the patients had serious adverse events
- the vector was found in samples of tears and blood only transiently after surgery
- Exposure to subretinal AAV at the doses used did not lead to a harmful immune response
- Patient 2 was found to have a macular hole at day 14 rather stable over time. This did not prevent vision improvement

All 12 patients reported improved vision in dimly lit environments in the injected eyes starting 2 weeks after surgery.

Outcome measures

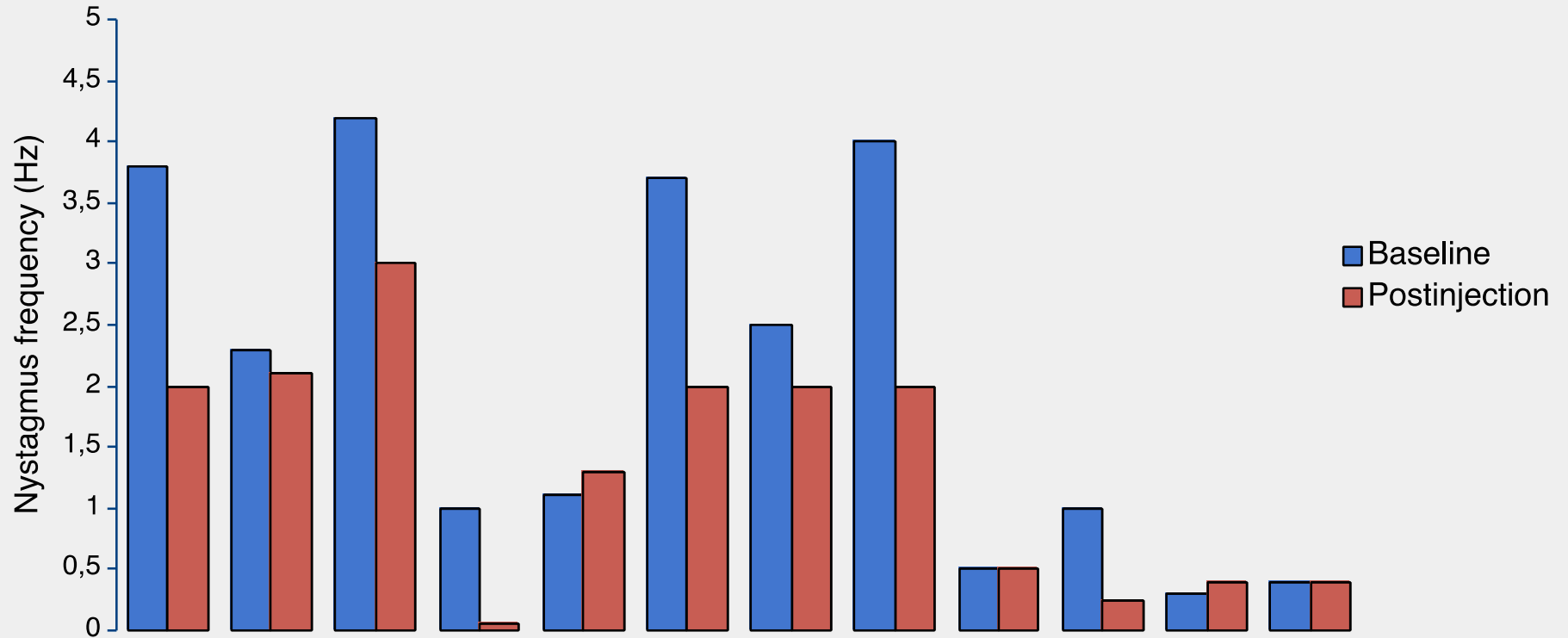
Objective measures:

- nystagmus testing
- pupillary light reflex
- Electroretinography

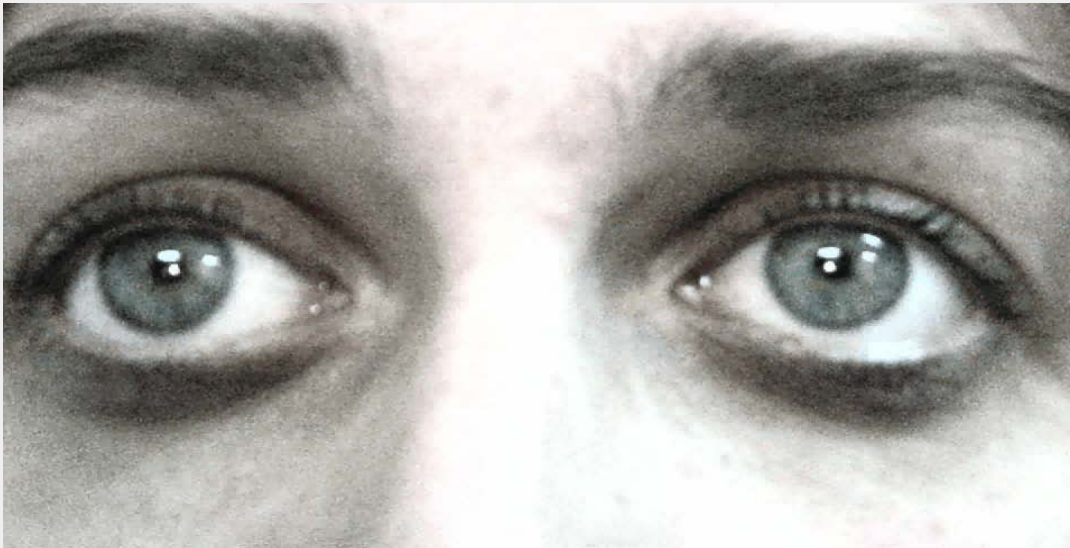Subjective measures:

- standard test of visual acuity
- Goldmann visual field
- mobility testing

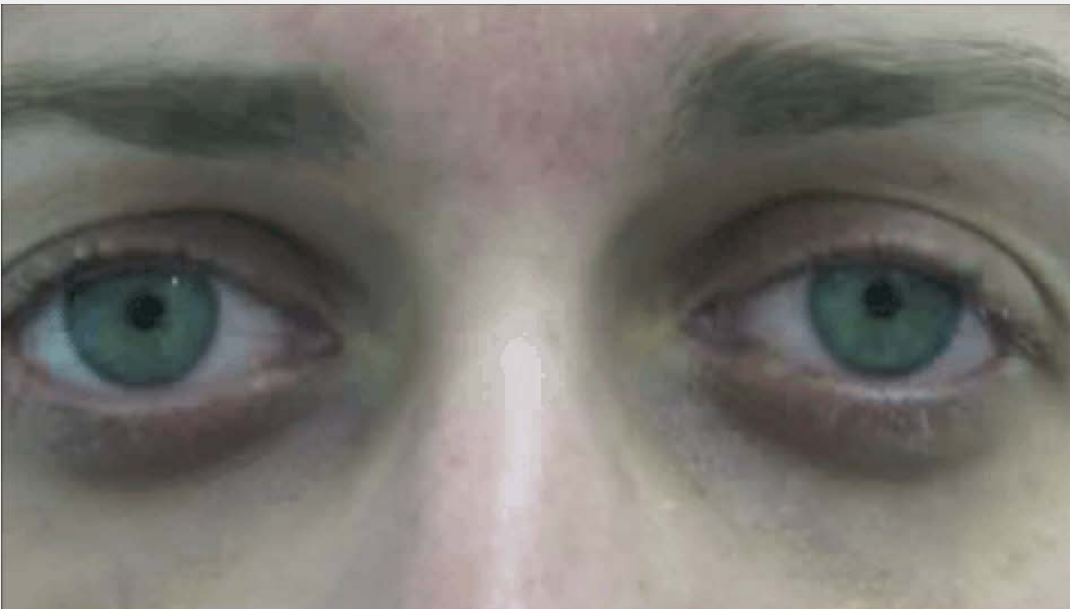nystagmus testing



NP03 - Nystagmus

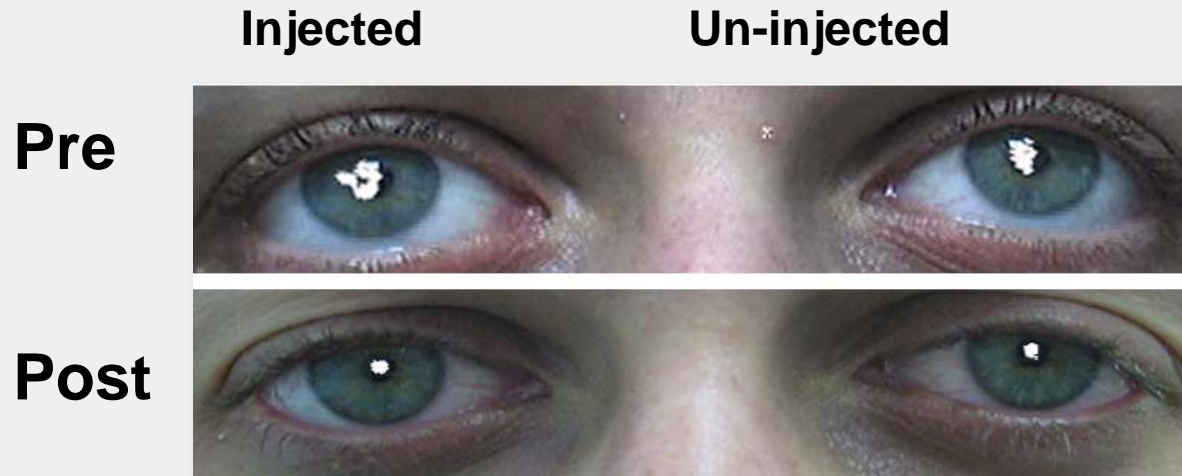

Before injection

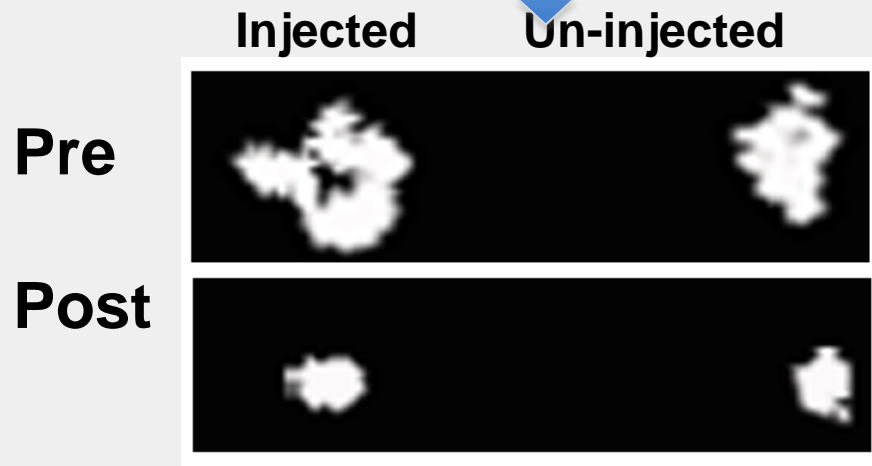

After injection

NP03: Nystagmus (3 Years Follow-up)



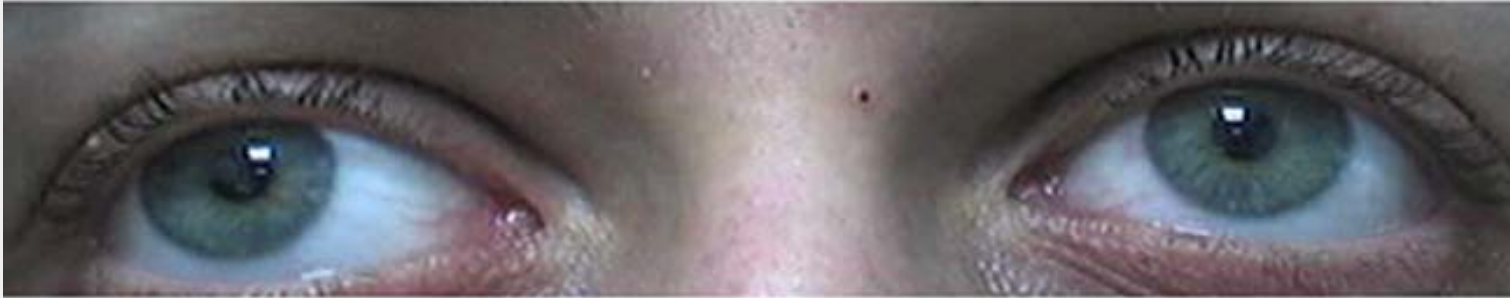Motion analysis
↓



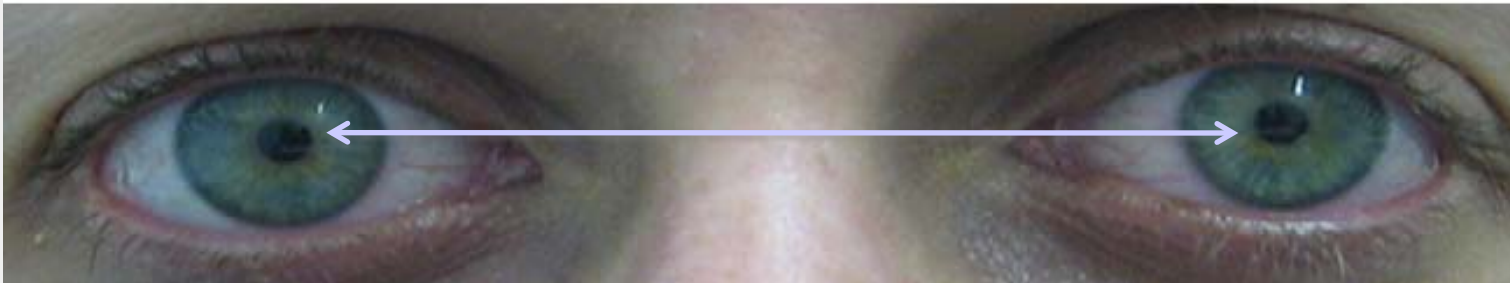Smaller excursion of nystagmus after injection in both eyes

NP03: Reduction in Exotropia (3 Years Follow-up)

Pre

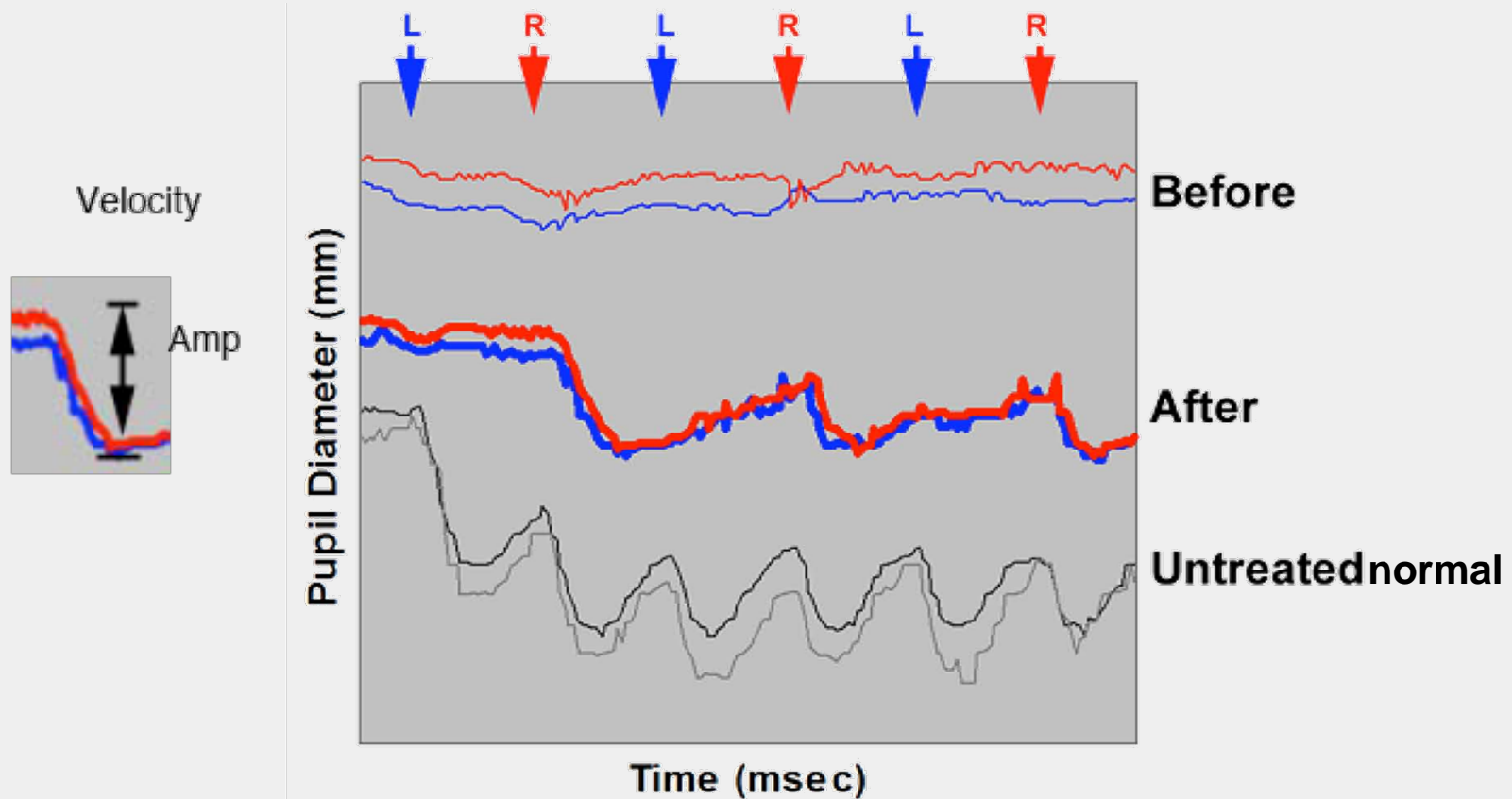


Post



Decreased inter-pupillary distance after injection

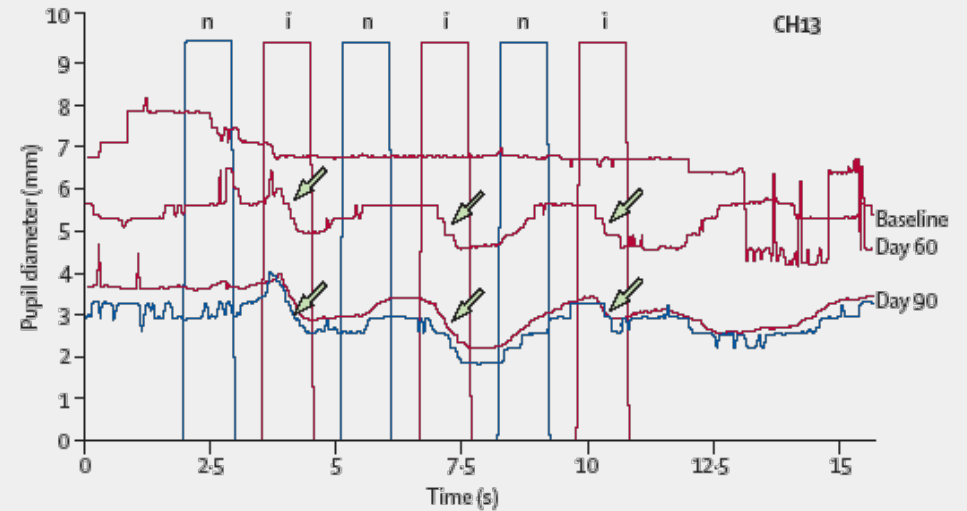
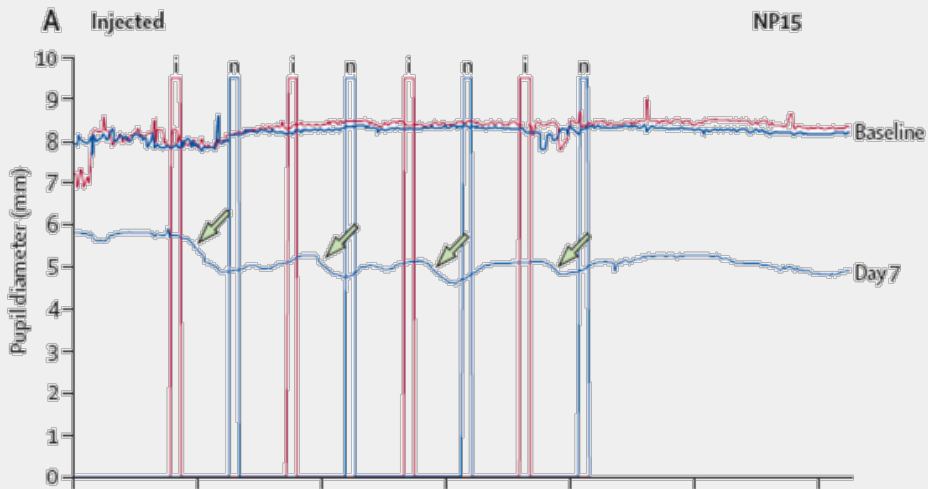
Pupillary Light Reflex (PLR)



Pupillometry provides quantitative information about the response of the entire retina to light

The improvements in the pupillary responses were easily assessed through measurement of the amplitude and velocity of constriction

Pupillary Light Reflex (PLR)

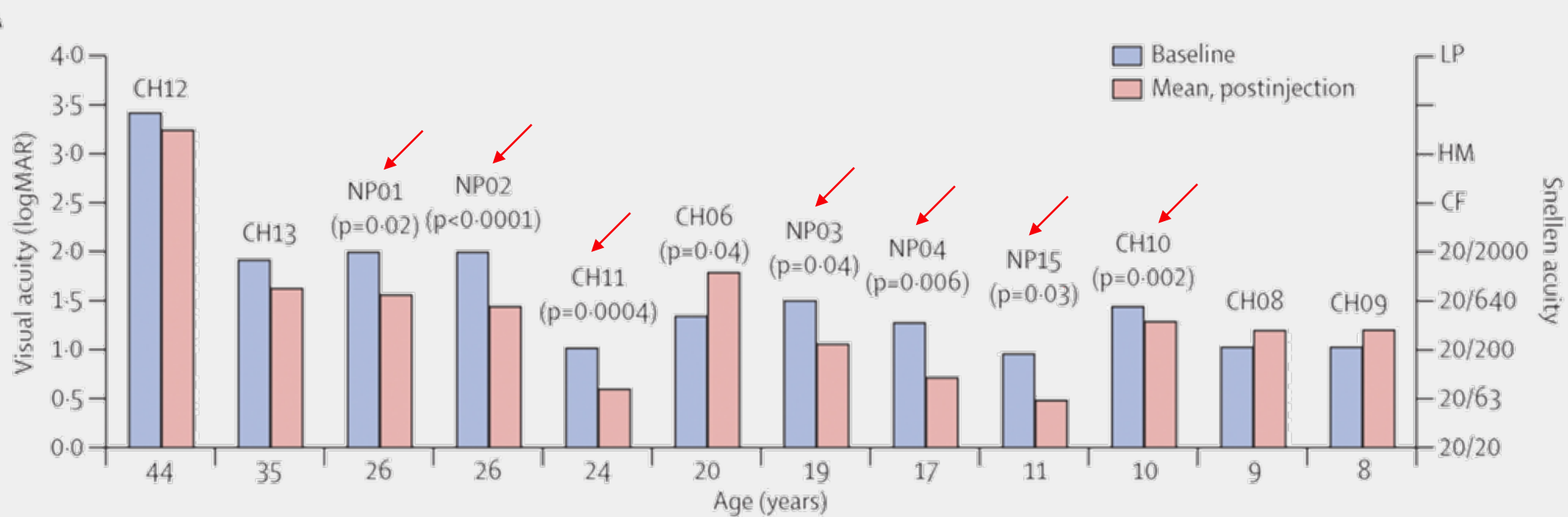


-PLR is restored in the injected eyes in all patients treated

Electroretinography

- Full field scotopic and photopic electroretinographic responses were flat in all patients before and after the injection.

Visual acuity




- Significant gains in visual acuity in 7/12 subjects
- Gains are stable

Visual acuity

(50 cm)

3 years




NPO3

Visual acuity

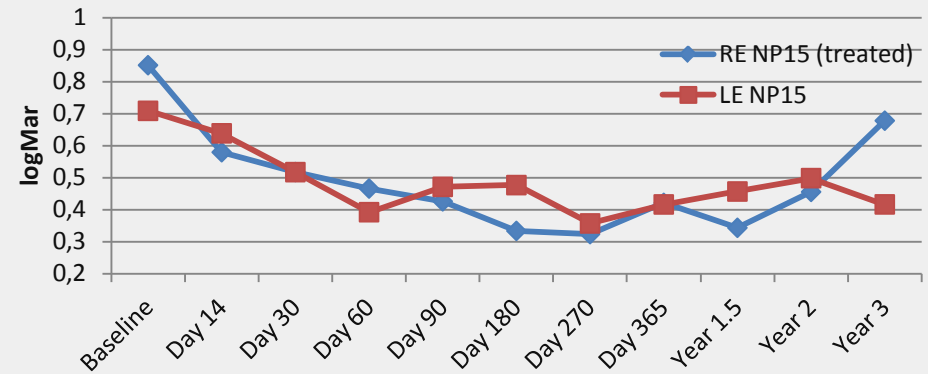
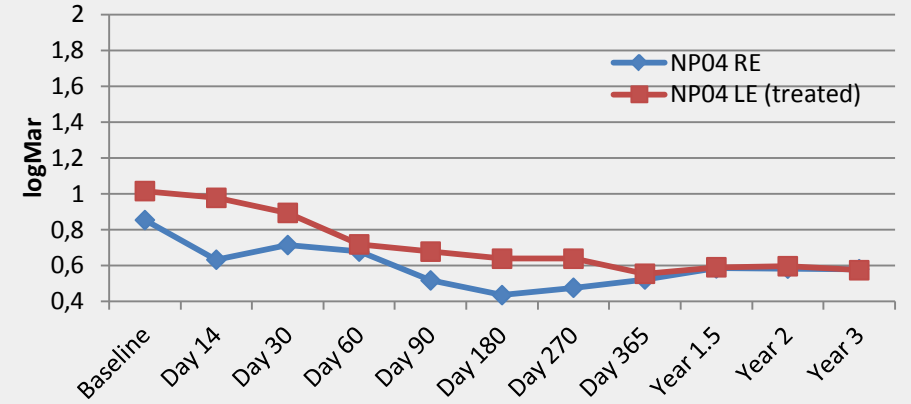
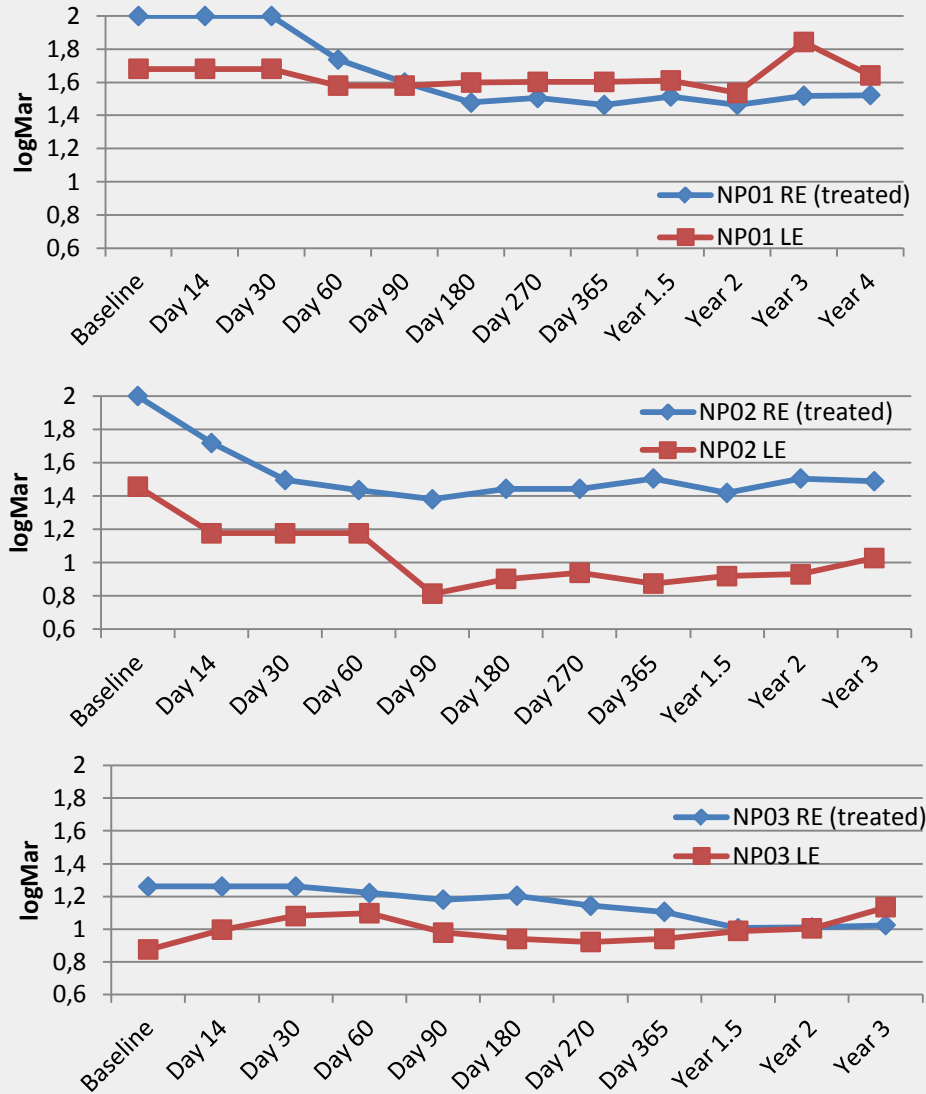
(2 meters)

3years




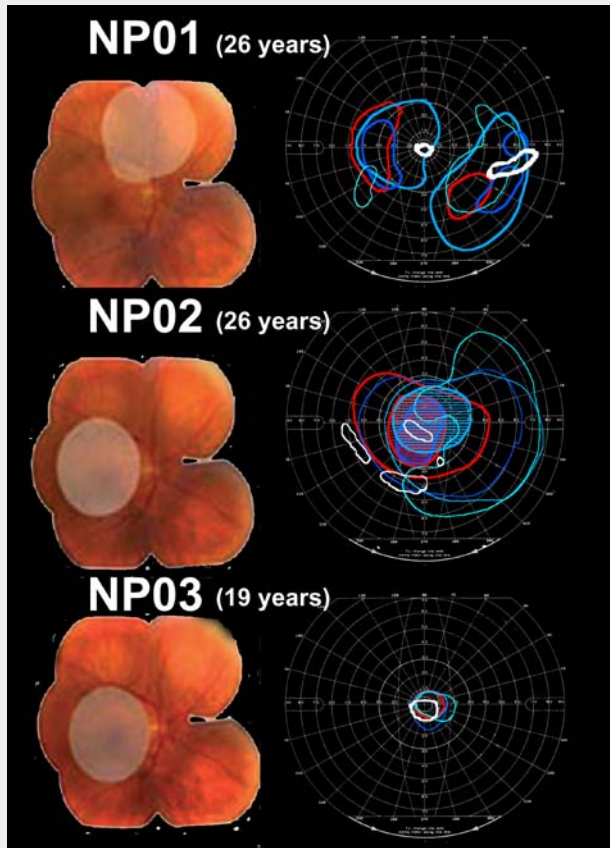
NP15

Longitudinal data analysis of Best Corrected Visual Acuity (BCVA) in all the patients



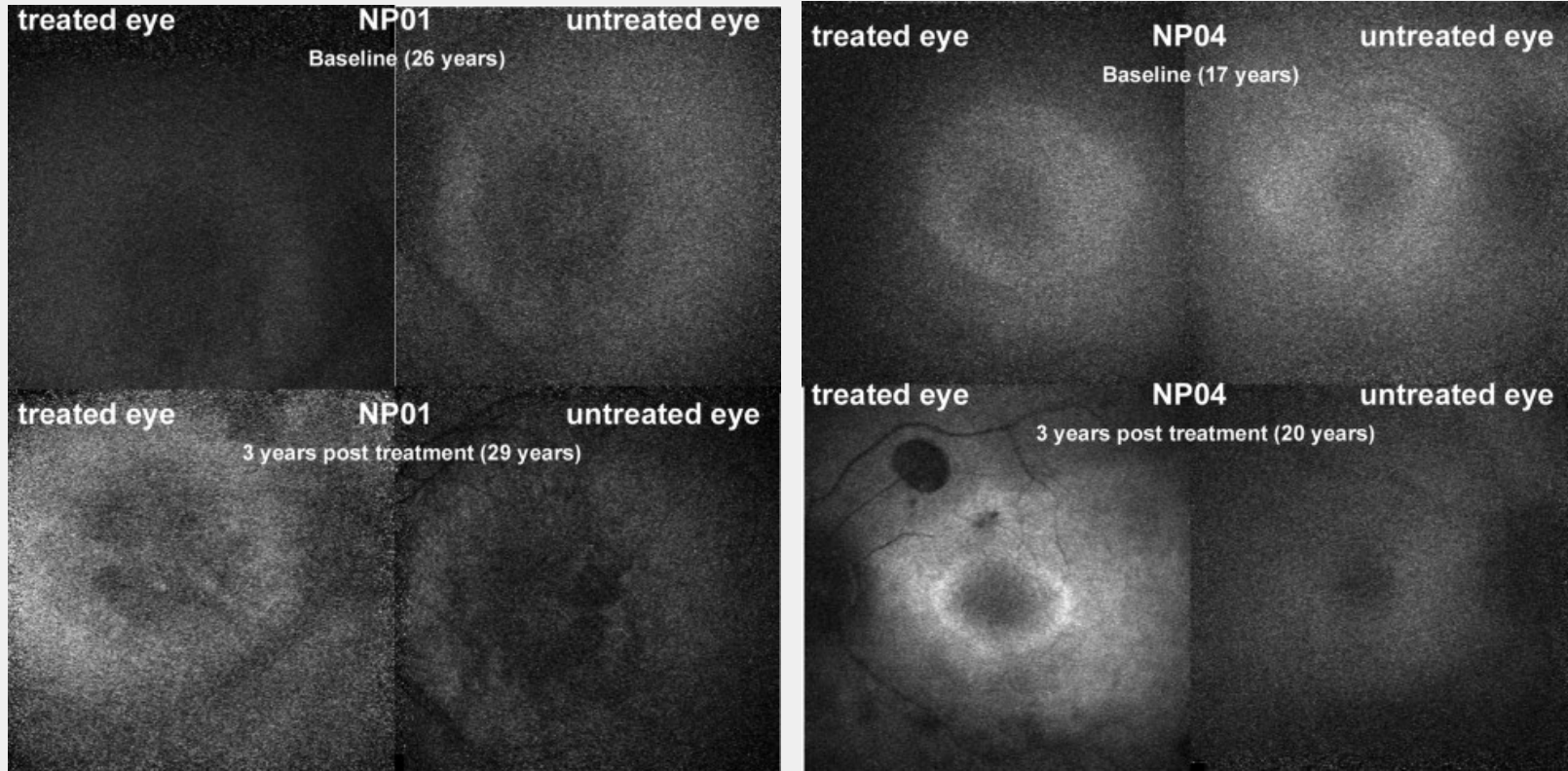
Testa F, Maguire AM, Rossi S, Pierce EA, Melillo P, Marshall K, Banfi S, Surace EM, Sun J, Acerra C, Wright JF, Wellman J, High KA, Auricchio A, Bennett J, Simonelli F, Three-Year Follow-up after Unilateral Subretinal Delivery of Adeno-Associated Virus in Patients with Leber Congenital Amaurosis Type 2. *Ophthalmology*. 2013

Visual field



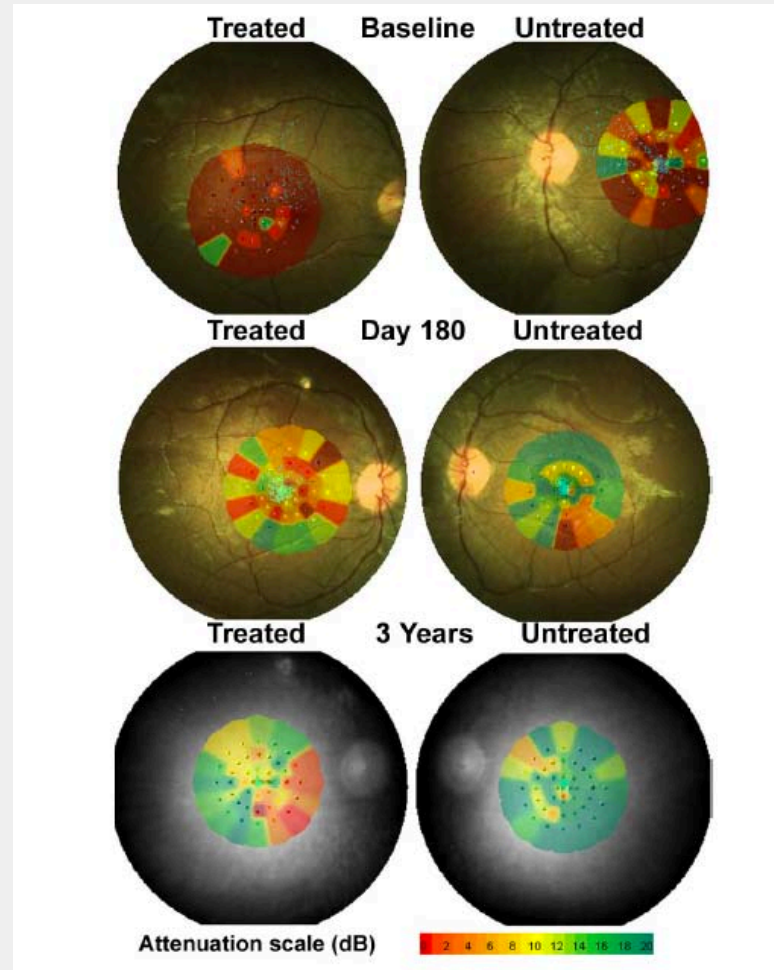
All subjects have expanded visual fields after injection
Expansion correlates with the area injected

Autofluorescence



Fundus autofluorescence (FAF) results of patients NP01 and NP04. An increase of FAF is shown in the treated eye compared with baseline and with the untreated eye.

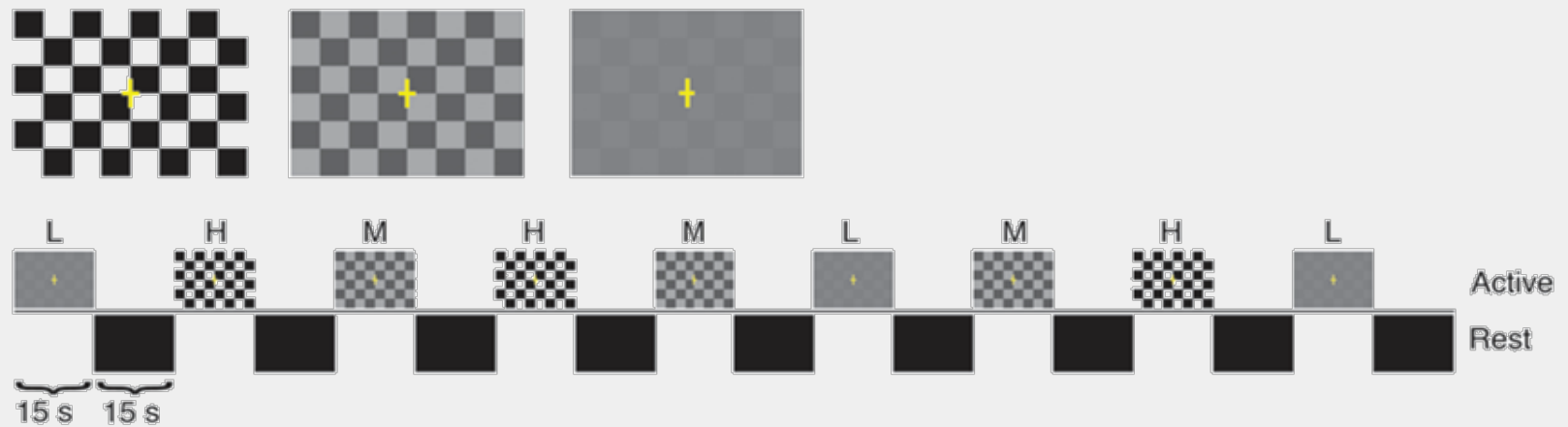
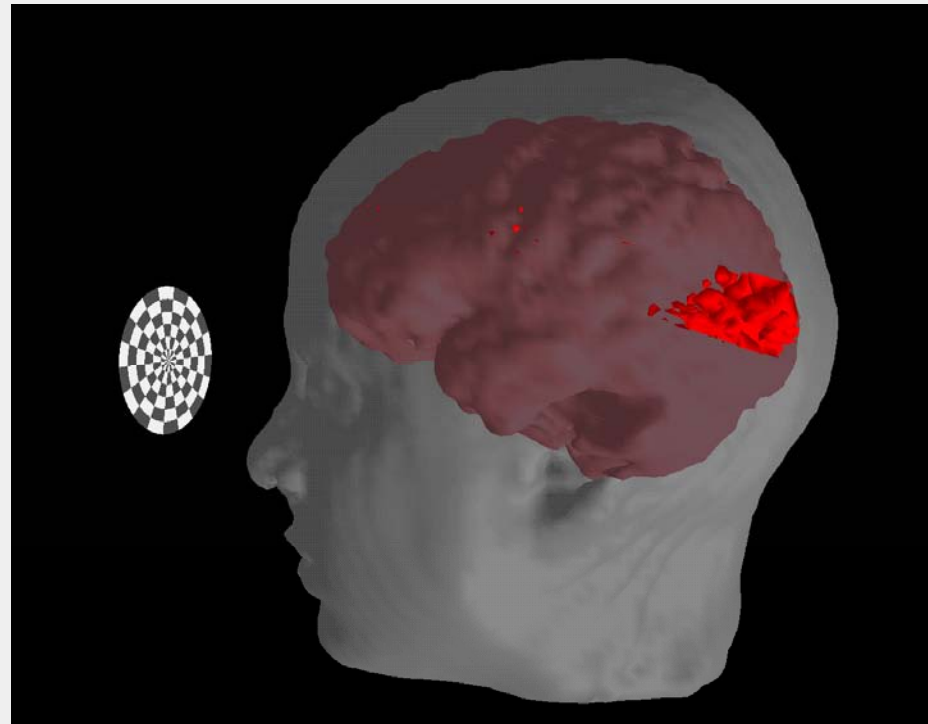
Microperimetry sensitivity map in NP15 at selected timepoints

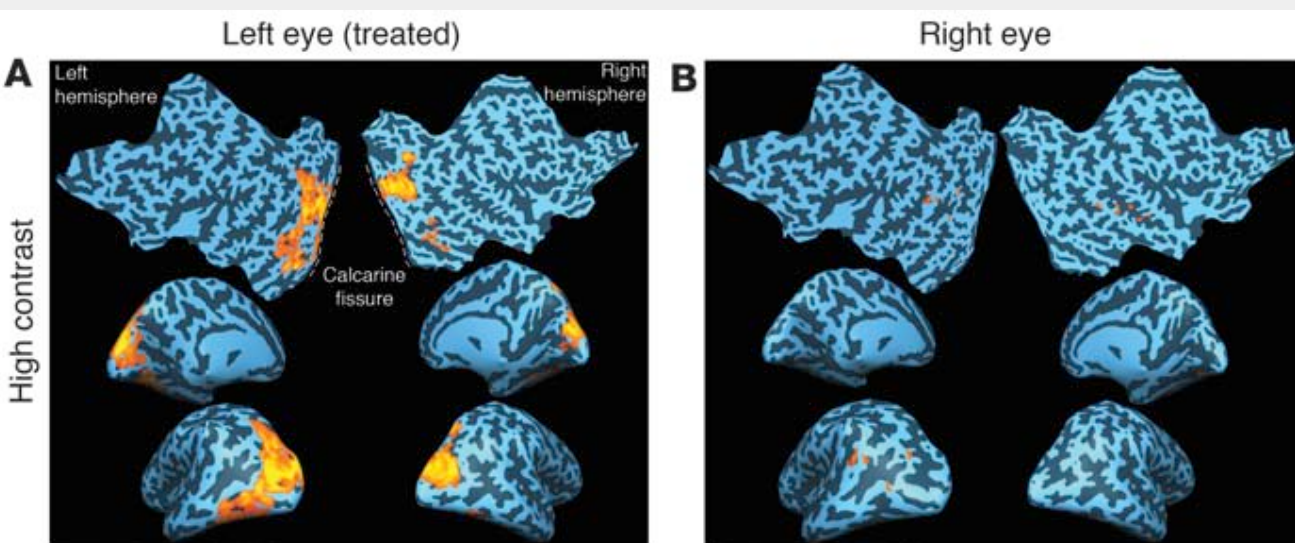
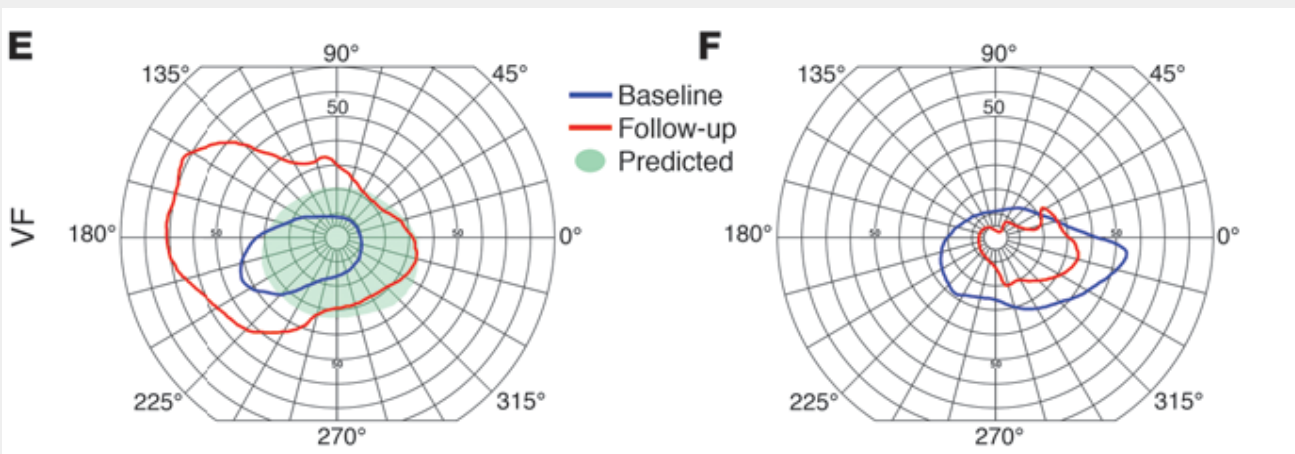
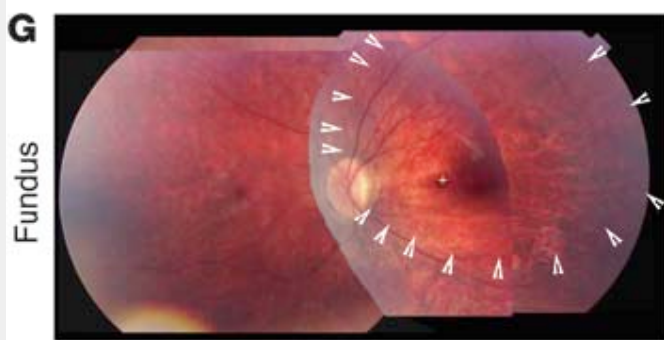


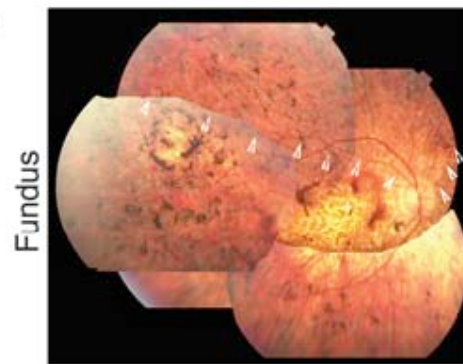
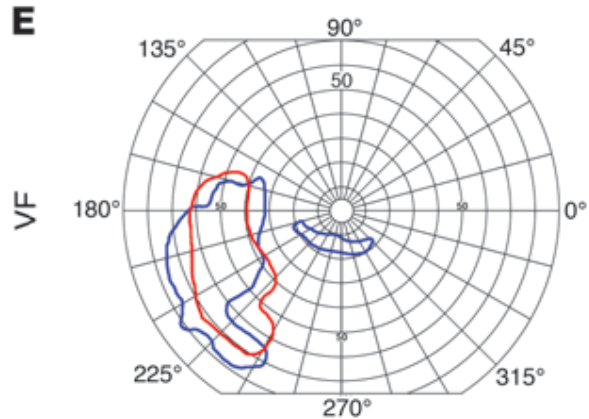
The longitudinal data analysis of microperimetry in NP15 shows a change of fixation from an unstable extrafoveal site to a stable foveal site.



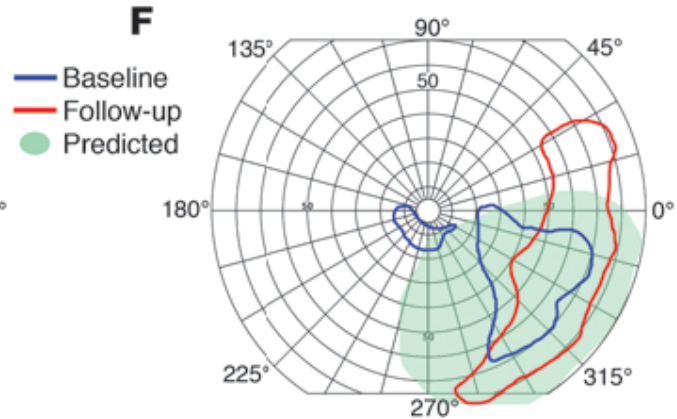
Functional MRI



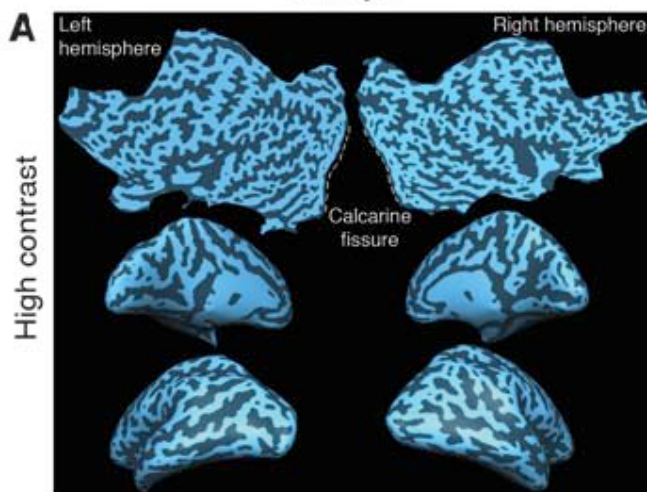


G**E**

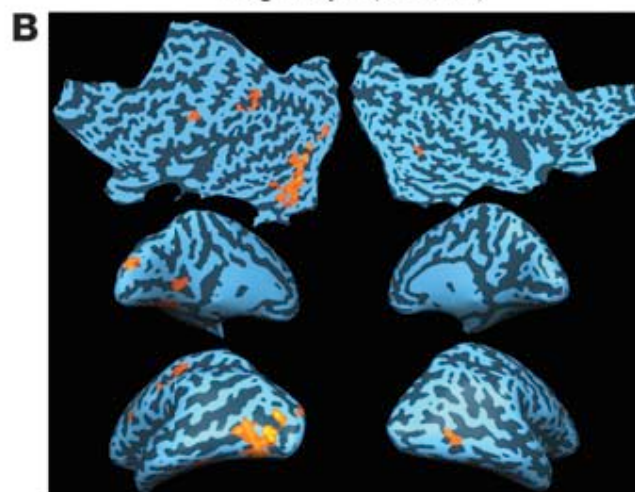
Left eye

F

Right eye (treated)

A

High contrast

B

CONCLUSION

- **There was no evidence of adverse effects of gene transfer on retinal function**
- **There was no evidence of systemic toxicity in the long-term study**

CONCLUSION

- **Most of the improvement occurs in the first six months after injection in all subjects**
- **The improvement is maintained in the treated patients up to 3 years post injection**
- **The visual recovery noted in the children confirms that the efficacy will be improved if treatment is applied before retinal degeneration has progressed.**

CONCLUSION

Gene therapy of LCA patients with RPE65 mutations appears safe and results in stable improvement in retinal/visual function after a single vector application

BRIEF REPORT

Safety and Efficacy of Gene Transfer for Leber's Congenital Amaurosis

Albert M. Maguire, M.D., Francesca Simonelli, M.D., Eric A. Pierce, M.D., Ph.D.,
Edward N. Pugh, Jr., Ph.D., Federico Mingozzi, Ph.D., Jeannette Bennicelli, Ph.D.,
Sandro Banfi, M.D., Kathleen A. Marshall, C.O.T., Francesco Testa, M.D.,
Enrico M. Surace, D.V.M., Settimio Rossi, M.D., Arkady Lyubarsky, Ph.D.,
Valder R. Arruda, M.D., Barbara Konkle, M.D., Edwin Stone, M.D., Ph.D.,
Junwei Sun, M.S., Jonathan Jacobs, Ph.D., Lou Dell'Osso, Ph.D.,
Richard Hertle, M.D., Jian-xing Ma, M.D., Ph.D., T. Michael Redmond, Ph.D.,
Xiaosong Zhu, M.D., Bernd Hauck, Ph.D., Olga Zelenaia, Ph.D.,
Kenneth S. Shindler, M.D., Ph.D., Maureen G. Maguire, Ph.D., J. Fraser Wright, Ph.D.,
Nicholas J. Volpe, M.D., Jennifer Wellman McDonnell, M.S., Alberto Auricchio, M.D.,
Katherine A. High, M.D., and Jean Bennett, M.D., Ph.D.

Gene Therapy for Leber's Congenital Amaurosis is Safe and Effective Through 1.5 Years After Vector Administration

Francesca Simonelli^{1,2}, Albert M Maguire³⁻⁵, Francesco Testa¹, Eric A Pierce^{3,5}, Federico Mingozzi⁴, Jeannette L Bennicelli^{3,5}, Settimio Rossi¹, Kathleen Marshall⁴, Sandro Banfi², Enrico M Surace², Junwei Sun⁴, T Michael Redmond⁶, Xiaosong Zhu⁴, Kenneth S Shindler^{3,5}, Gui-Shuang Ying³, Carmela Ziviello^{2,7}, Carmela Acerra^{1,2,4}, J Fraser Wright^{4,5}, Jennifer Wellman McDonnell⁴, Katherine A High^{4,5,8}, Jean Bennett^{3,4} and Alberto Auricchio^{2,9}

Age-dependent effects of RPE65 gene therapy for Leber's congenital amaurosis: a phase 1 dose-escalation trial



Albert M Maguire^{}, Katherine A High^{*}, Alberto Auricchio, J Fraser Wright, Eric A Pierce, Francesco Testa, Federico Mingozzi, Jeannette L Bennicelli, Gui-shuang Ying, Settimio Rossi, Ann Fulton, Kathleen A Marshall, Sandro Banfi, Daniel C Chung, Jessica I W Morgan, Bernd Hauck, Olga Zelenai, Xiaosong Zhu, Leslie Raffini, Frauke Coppieters, Elfride De Baere, Kenneth S Shindler, Nicholas J Volpe, Enrico M Surace, Carmela Acerra, Arkady Lyubarsky, T Michael Redmond, Edwin Stone, Junwei Sun, Jennifer Wellman McDonnell, Bart P Leroy, Francesca Simonelli, Jean Bennett*



The human visual cortex responds to gene therapy–mediated recovery of retinal function

Manzar Ashtari,¹ Laura L. Cyckowski,¹ Justin F. Monroe,¹ Kathleen A. Marshall,² Daniel C. Chung,^{2,3}
Alberto Auricchio,^{4,5} Francesca Simonelli,^{4,5,6} Bart P. Leroy,⁷ Albert M. Maguire,^{2,3}
Kenneth S. Shindler,³ and Jean Bennett^{2,3}

¹Department of Radiology and ²Center for Cellular and Molecular Therapeutics, Children's Hospital of Philadelphia (CHOP), Philadelphia, Pennsylvania, USA.

³F.M. Kirby Center for Molecular Ophthalmology, Scheie Eye Institute, University of Pennsylvania School of Medicine, Philadelphia, Pennsylvania, USA.

⁴Telethon Institute of Genetics and Medicine (TIGEM) and ⁵Medical Genetics, Department of Pediatrics, "Federico II University," Naples, Italy.

⁶Second University of Naples, Naples, Italy. ⁷Department of Ophthalmology and Center for Medical Genetics, Ghent University and Ghent University Hospital, Ghent, Belgium.

AAV2 Gene Therapy Readministration in Three Adults with Congenital Blindness

Jean Bennett,^{1,2,*†} Manzar Ashtari,^{3,*†} Jennifer Wellman,² Kathleen A. Marshall,²
Laura L. Cyckowski,³ Daniel C. Chung,^{1,2} Sarah McCague,² Eric A. Pierce,^{1,4‡} Yifeng Chen,²
Jeannette L. Bennicelli,¹ Xiaosong Zhu,⁴ Gui-shuang Ying,⁵ Junwei Sun,² J. Fraser Wright,²
Alberto Auricchio,^{6,7} Francesca Simonelli,^{6,8} Kenneth S. Shindler,¹ Federico Mingozzi,²
Katherine A. High,^{2,9} Albert M. Maguire^{1,2,4}

Three-Year Follow-up after Unilateral Subretinal Delivery of Adeno-Associated Virus in Patients with Leber Congenital Amaurosis Type 2

Francesco Testa, MD, PhD,¹ Albert M. Maguire, MD,^{2,3,4} Settimio Rossi, MD,¹ Eric A. Pierce, MD, PhD,^{2,4} Paolo Melillo, PhD,¹ Kathleen Marshall, COT,³ Sandro Banfi, MD,^{5,6} Enrico M. Surace, DVM,⁵ Junwei Sun, MS,⁴ Carmela Acerra, BA,¹ J. Fraser Wright, PhD,^{3,4} Jennifer Wellman, MS,³ Katherine A. High, MD,^{3,4,7} Alberto Auricchio, MD,^{5,8} Jean Bennett MD, PhD,^{2,3} Francesca Simonelli, MD^{1,5}

Ophthalmology 2013

Albert M. Maguire, Francesca Simonelli, Eric A. Pierce, Edward N. Pugh, Jr., Federico Mingozzi, Jeannette Bennicelli, Sandro Banfi, Kathleen A. Marshall, Francesco Testa, Enrico M. Surace, Settimio Rossi, Arkady Lyubarsky, Valder R. Arruda, Barbara Konkle, Edwin Stone, Junwei Sun, Jonathan Jacobs, Lou Dell'Osso, Richard Hertle, Jian-xing Ma, T. Michael Redmond, Xiaosong (Sonia) Zhu, Bernd Hauck, Olga Zeleniaia, Kenneth S. Shindler, Maureen G. Maguire, J. Fraser Wright, Nicholas J. Volpe, Jennifer Wellman McDonnell, Alberto Auricchio, Katherine A. High, Jean Bennett



